

PROCEEDINGS
of the
Society of Magnetic Resonance

Volume 3

Second Meeting
August 6-12, 1994
San Francisco, California USA

ISSN 1065-9889

Variations in the MR Characteristics of Breast Tissue during the Menstrual Cycle

S.J. Graham, P.L. Stanchev, M.J. Bronskill, and D.B. Plewes
Sunnybrook Health Science Centre, University of Toronto, Toronto, Ontario, Canada

The use of magnetic resonance (MR) to generate high contrast images of breast tissue continues to increase. It is important, therefore, to determine whether MR parameters are sensitive to the changes in breast tissue induced by sex hormones during the menstrual cycle. If changes are detectable, they may suggest a time interval that provides optimal contrast between breast tumours and normal parenchyma. In addition, MR may have potential as a research tool for non-hazardous measurement of the effects of exogenous or abnormal hormone levels on breast tissue. Previous studies have produced conflicting results; experiments at 0.08 T (1) and 0.15 T (2) have shown moderate changes (~10%) in T1 and water content, but experiments at 1.5 T (3,4) have shown no variations in proton density, T1, or T2. Most of these studies relied extensively on standard spin echo pulse sequences that provide sub-optimal estimates of quantitative MR parameters. In this study, we use state-of-the-art imaging methods to investigate variations in breast water content during the menstrual cycle at 1.5 T.

Three female subjects were included in the study, each menstruating regularly, ranging in age from 24 to 33. All were nulliparous and none utilized oral contraceptives or other synthetic hormones. MR examinations were performed bi-weekly for up to 36 days during which the dates for the start and end of menses were recorded. Both breasts were suspended in a single-loop elliptical surface coil and coronal slices 5 mm thick were acquired to encompass the entire breast volume. The 3-point Dixon method (TE=20/TR=1000) was used to obtain images of fat, water, and B_0 inhomogeneity. Images of relative water content (WC) were calculated from the relationship

$$WC_{ij} = \frac{0.9 \cdot W_{ij}}{0.9 \cdot W_{ij} + F_{ij}} \times 100\%$$

where W_{ij} and F_{ij} are the signal intensities from the water and fat images at pixel location (i,j) respectively, and the factor 0.9 accounts for the difference in proton density between water and fat molecules. The mean relative water content, $\langle WC \rangle$, was then calculated for the left, the right, and both breasts by pixel averaging. The relative volume of fibroglandular tissue (FV) was estimated from the pixel histogram of WC, assuming that the adipose and fibroglandular tissue could be separated using an arbitrary threshold of WC = 60 % (Fig. 1).

Plots of $\langle WC \rangle$ and FV differed widely among the subjects investigated, ranging from marked cyclic variations in a subject with appreciable amounts of fibroglandular tissue (Fig. 2) to undetectable variations in a subject with small amounts of fibroglandular tissue (FV < 5 %). For each subject, good agreement was found between measurements of the left and right breast, and between $\langle WC \rangle$ and FV. Two subjects with cyclic variations showed a similar pattern, with $\langle WC \rangle$

and FV decreasing in the first week of the follicular phase, slowly increasing until mid-luteal phase, then rapidly increasing to a maximum at the onset of menses. Changes in $\langle WC \rangle$ and FV were similar to those obtained in previous low field studies (1,2). These results are qualitatively consistent with the known effects of estrogen and progesterone on the breast epithelium and stroma (5).

References

1. P.A. Fowler, C.E. Casey, G.G. Cameron, et al., *Br. J. Ob. Gyn.* 97:595-602 (1990).
2. T.R. Nelson, D.H. Pretorius, L.M. Schiffer, *J. Comput. Assist. Tomogr.* 9:875-879 (1986).
3. B. Martin and S.J. El Yousef, *J. Comput. Assist. Tomogr.* 10:924-927 (1986).
4. L.M. Jawnny, A. Wicks, J.P. Hornak, et al., Society of Magnetic Resonance in Medicine 12th Annual Meeting, New York, 1993, Abstract No. 858.
5. T.A. Longacre, and S.A. Bartow, *Am. J. Surg. Pathol.* 10(6):382-393, 1986.

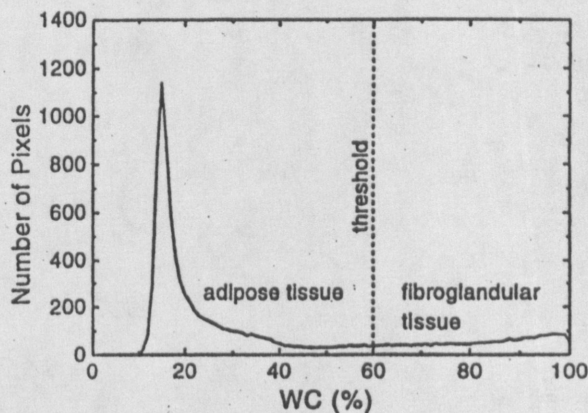


Figure 1. Pixel histogram of breast relative water content.

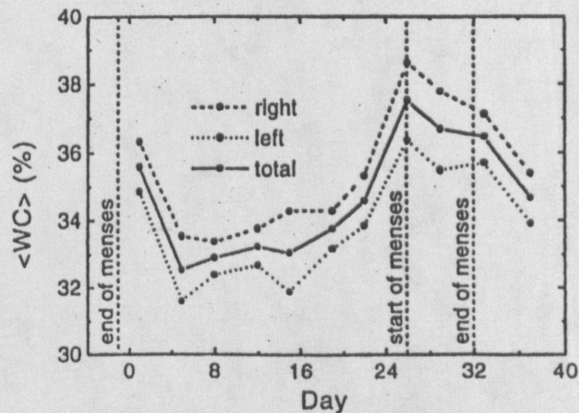


Figure 2. Breast mean relative water content versus time.

- (54.) Graham S., Stanchev P., Bronskill M., Plewes D., "Variations in the MR Characteristics of Breast Tissue during the Menstrual Cycle", *Proceedings of the Society of Magnetic Resonance, Second Meeting*, August 1994, 1467.